

Saving Natural Root Pieces with Post-and-Core and Polymer Reinforced Crowns: A Clinical Case Series

Chirag Chamria*

Department of Surgery, Royal Dental Clinics, India

Submission: December 22, 2025; Published: January 17, 2026

***Corresponding author:** Chirag Chamria, Department of Surgery, Royal Dental Clinics, 79 VMall Thakur Complex, Kandivali East, 400101, Mumbai, India.

ABSTRACT

Background: Teeth with minimal remaining coronal structure are often considered candidates for extraction and implant placement. However, extensive evidence shows that endodontically treated teeth restored with an adequate ferrule, post-and-core support, and cuspal coverage exhibit long-term success comparable to implants ^[1-6].

Objective: To describe three clinical situations in which severely damaged crowns with sound roots were restored using post-and-core build-ups and polymer-reinforced CAD-CAM crowns, avoiding extraction and implant therapy.

Cases:

Case 1: A fractured maxillary anterior tooth with near-total coronal loss was restored using a metal stock post, composite core, and a polymer-reinforced crown, achieving esthetics and function.

Case 2: A mandibular posterior tooth with negligible supragingival structure was rehabilitated using post-and-core reinforcement and a full-coverage polymer-reinforced crown, enabling long-term occlusal loading.

Case 3: A full-mouth rehabilitation case with generalized advanced coronal destruction but healthy roots was managed through strategic endodontics, post-and-core build-ups, and full-arch polymer-reinforced restorations, preserving natural dentition while restoring function and esthetics.

Conclusion: When roots are periodontally sound and a ferrule effect can be established, post-and-core restorations supported by modern adhesive protocols and shock-absorbing polymer-reinforced prostheses offer a biologically conservative, durable, and cost-efficient alternative to extraction and implants. The decision to preserve or remove a tooth must integrate periodontal, endodontic, occlusal, and prosthetic factors—highlighting that “hopeless-looking” crowns do not necessarily equate to hopeless teeth.

INTRODUCTION

Endodontically treated teeth (ETT) with extensive coronal destruction pose a classic dilemma: save the root with post-and-core and crown, or extract and replace with an implant. Contemporary systematic reviews show that ETT restored with posts have high survival rates, often above 90% at 5 years, with no clinically relevant difference between glass-fiber and metal posts when indications are respected [1,2,6,11,12].

Fracture resistance is strongly linked to the amount and configuration of remaining coronal tooth structure, particularly the presence of a 1.5–2.0 mm circumferential ferrule [3–5,13]. Indirect restorations (crowns, onlays) over sound cores tend to outperform large direct restorations in medium-term survival and success [3,4].

More recently, polymer-reinforced PMMA biopolymers (e.g., G-CAM by Graphenano Dental or HIPC by Bredent) have emerged as lightweight, high-strength CAD-CAM materials suitable for long-term crowns and full-arch prostheses [11,14–16]. These materials show improved mechanical performance, wear resistance and promising colour stability compared with conventional PMMA [14–16]. Their shock-absorbing behaviour can be particularly advantageous when rebuilding entire arches over multiple posts.

This case series illustrates how the combination of evidence-based post-and-core protocols and polymer reinforced crowns can be used to save natural root pieces in both single-tooth and full-arch situations.

CASE SERIES

Case 1: Single Fractured Anterior Tooth (Ellis Class VIII -type) Restored with Post and Core

Chief complaint:

A middle-aged patient presented with a broken upper front tooth and inability to smile confidently.

History and diagnosis:

The maxillary right central incisor had suffered trauma several years earlier. The clinical crown was almost completely lost, with a short-discoloured root fragment remaining at the gingival margin as shown in Figure 1.

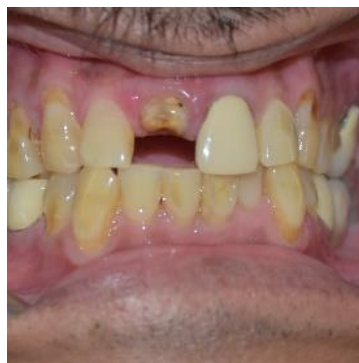

Figure 1: Case 1 Pre-operative.

Radiographic examination revealed as shown in Figure 2:

- Adequate root length and apical seal following previous root canal treatment.
- Intact lamina dura and acceptable crown: root ratio if a ferrule could be established.
- No periapical pathology or root fracture.

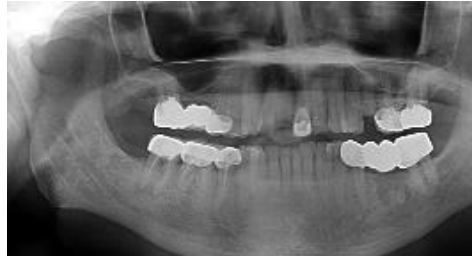

Figure 2: Case-1 Pre-operative OPG.

Diagnosis: Previously root canal -treated tooth with severe coronal breakdown (Ellis Class VIII) but with good root prognosis.

Treatment options discussed:

1. Extraction and single implant-supported crown.
2. Root submergence and adjacent tooth-supported FPD/pontic
3. Retreatment, post-and-core build-up, and definitive crown.

Considering the sound root, favourable bone support, and patient's preference to avoid implant surgery, option 3 was selected, aligning with evidence supporting high survival of well-restored ETT with posts and cuspal coverage^[1-4,6].

Clinical procedure:

1. **Endodontic evaluation and revision:** Existing root canal was reassessed; minor touch-up and obturation refinement were performed to ensure a homogenous fill.
2. **Post-space preparation:** Gutta-percha was removed leaving at least 4–5 mm apical seal. Post space was prepared with dedicated drills, respecting root curvature and diameter to avoid thinning the dentinal walls.
3. **Post selection and placement:** A stock metal post was selected^[1,2,11,12]. Adhesive protocol: GIC luting type was used as shown in Figure 3.

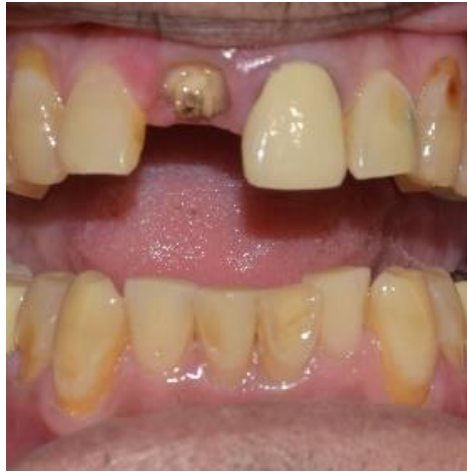

Figure 3: Case 1 During treatment.

4. Core build-up: A nanohybrid resin composite core was built incrementally to recreate the missing coronal structure and allow a >1.5 mm ferrule on the sound root at the cervical level, in line with literature on ferrule effect [3-5,13]. Gingival crown lengthening procedure was performed to get adequate height.

5. Tooth preparation: A conservative shoulder/chamfer finish line was placed at or slightly supragingival where possible.

6. Definitive polymer reinforced crown: Digital impression was taken and a CAD-CAM milled polymer crown was fabricated.

- The material's graphene-reinforced biopolymer matrix offers high strength, low weight and favourable wear profile [11,14-16].
- The crown was adhesively luted, and occlusion adjusted to avoid eccentric overload as shown in Figure 4.

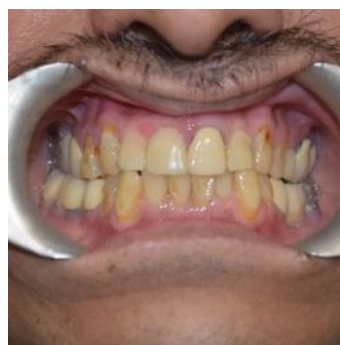

Figure 4: Case 1 Post-operative.

Follow-up:

At 3 year review, the tooth remained asymptomatic, with stable gingival margins, satisfactory colour integration and intact post-core–crown complex as shown in Figure 5.

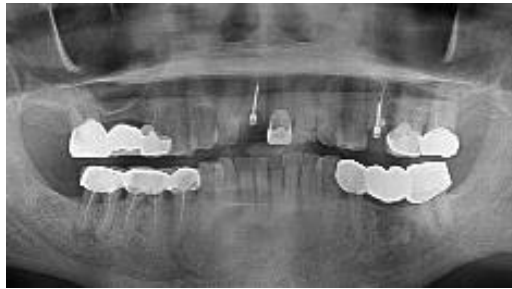

Figure 5: Case-1 Post-operative OPG.

Case 2: Single Fractured Posterior Tooth Restored with Post and Core**Chief complaint:**

A patient reported difficulty chewing on the lower right back side tooth region due to a “half-broken” right molar.

Clinical findings:

- Mandibular first molar with extensive coronal destruction; only thin circumferential dentinal walls above the gingiva as shown in Figure 6.

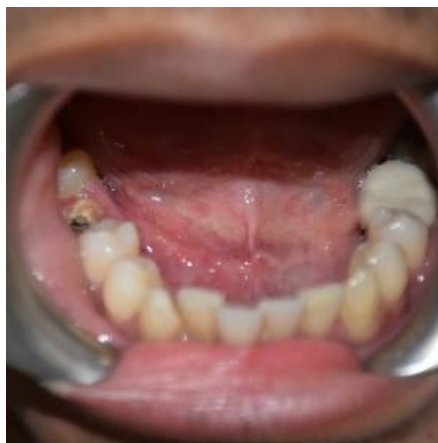

Figure 6: Case 2 Pre-operative.

- Tooth was previously root canal treated; percussion negative, periodontal probing within normal limits.
- Radiograph showed good root length, proper obturation, with no periapical lesion as shown in Figure 7.

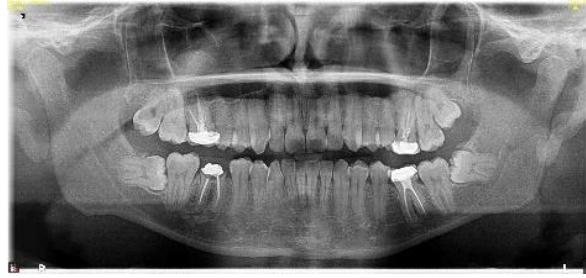


Figure 7: Case 2 OPG.

Diagnosis: Endodontically treated mandibular molar with negligible coronal structure but favourable root support.

Treatment considerations:

While extraction and implant were possible, a post-and-core with full-coverage crown was chosen—supported by data showing high survival of posterior ETT restored with indirect restorations and proper ferrule [3,4,6].

Clinical Procedure:

1. **Core and ferrule planning:** Remaining walls were evaluated; where possible, small cuspal buttresses were preserved to improve resistance form, consistent with studies emphasizing the value of residual tooth structure.^{cx}
2. **Post-space preparation and post selection:** The distal and MB canal was prepared as the main post channel to minimize the risk of root perforation. A **stock metal reinforced post** was adhesively cemented; other canals were left filled with gutta-percha.
3. **Core build-up:** A dual-cure core build-up material was used to recreate missing cusps. Cuspal coverage design was planned at this stage, anticipating occlusal loading patterns as shown in Figure 8.

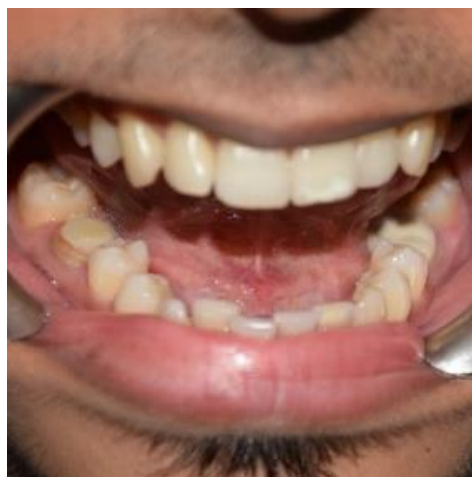

Figure 8: Case 2 During treatment.

4. **Tooth preparation and provisionalization:** A full-coverage crown preparation with functional cusp bevels and rounded internal angles was done. A provisional crown was cemented to monitor occlusion and soft tissue.

Citation: Chirag Chamria (2025) Saving Natural Root Pieces with Post-and-Core and Polymer Reinforced Crowns: A Clinical Case Series. On J Clin & Med Case Rep 2(1): 1-13.

5. **Definitive graphene-reinforced crown:** A polymer based CAD-CAM crown was fabricated, designed to distribute masticatory forces across the post-core and root. The relatively low modulus and shock-absorbing behaviour of graphene-reinforced PMMA may reduce catastrophic root fracture risk compared with very stiff ceramics in such compromised roots [14-16]. Crown was luted with adhesive resin cement and occlusion carefully refined as shown in Figure 9.

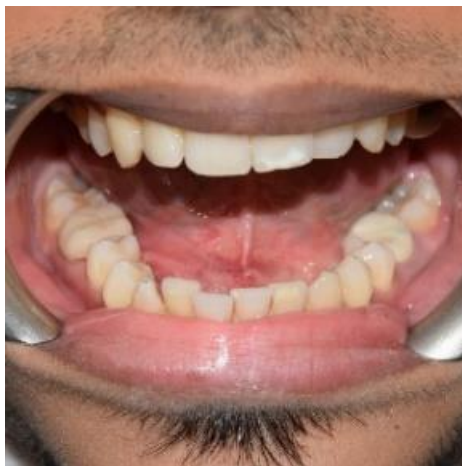

Figure 9: Case 2 Post-operative.

Follow-up:

At 2 months, patient reported comfortable chewing; no signs of marginal leakage, post debonding or root fracture were observed.

Case 3: Full-Mouth Rehabilitation with Post-and-Core Build-ups

Chief complaint:

A patient presented with generalized “short, worn and broken teeth”, difficulty in chewing and was having poor smile esthetics.

Examination:

- Severe generalized attrition and multiple Ellis Class V-type crown losses; several teeth had only stump-like fragments above the gingiva as shown in Figure 10.

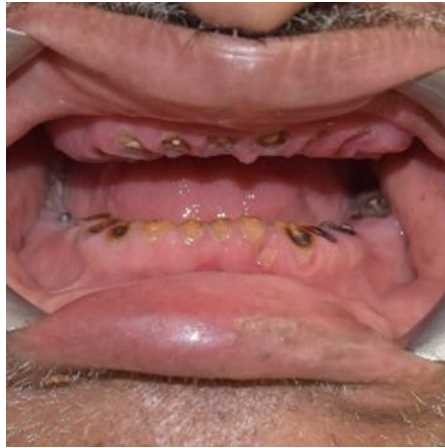

Figure 10: Case 3 Pre-operative.

- Radiographs and CBCT showed:
 - a. Mostly intact root structures with adequate bone support as shown in Figure 11.
 - b. A few non-restorable teeth indicated for extraction.
- Periodontal status: overall maintainable with moderate chronic periodontitis controlled by initial therapy.

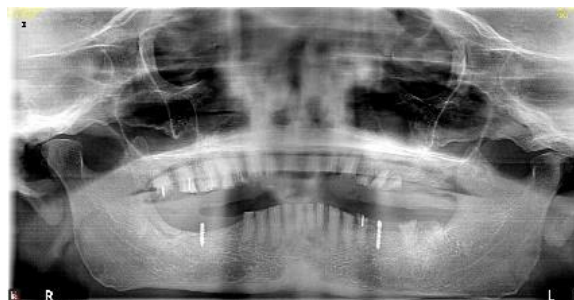

Figure 11: Case 3 Pre-operative OPG.

Treatment philosophy:

Given the good roots but destroyed crowns, the options were:

1. Multiple extractions with full-arch implants and rigid metal-ceramic/zirconia prostheses.
2. Strategic endodontics, post-and-core build-ups and full-arch crowns on natural teeth, with selective extractions.

Based on patient preference for a more conservative, staged and cost-effective plan, and the evidence that well-restored ETT can achieve long-term survival comparable to implants in many situations ^[1,3,4,6] option 2 was chosen.

Treatment sequence:

1. **Disease Control Phase:** Comprehensive periodontal therapy, caries control and extractions of non-restorable teeth.
 - a) **Endodontic and post-and-core phase:** Root canal treatments or retreatments were completed on strategic abutment teeth. Post-space preparation and stock metal post placement were performed on teeth with <30% coronal structure remaining, supported by meta-analyses showing favourable survival when posts are properly indicated [2,6,11,12,17]. Composite or dual-cure cores were built to restore anatomical crown height and allow a continuous circumferential ferrule wherever possible as shown in Figure 12.

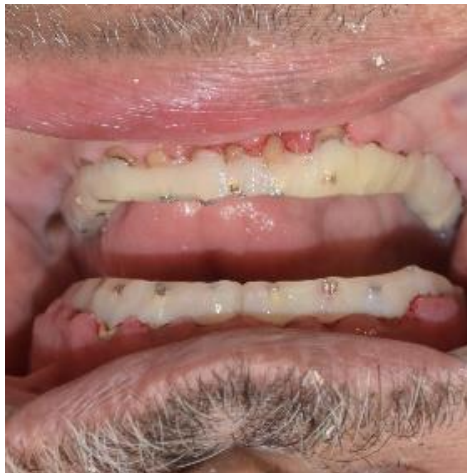

Figure 12: Case 3 During treatment.

2. **Definitive polymer reinforced crowns:** Full-arch scans were taken. **CAD-CAM crowns and bridges** were fabricated for both arches. The material's high strength-to-weight ratio and resilience make it suitable for full-arch prostheses while reducing weight compared with metal-ceramic frameworks [11,14-16]. Crowns were adhesively bonded while optimizing force distribution and allowing future maintenance.

Outcomes:

- **Esthetic outcome:** Significant improvement in smile line, tooth display and facial support as shown in Figure 13.

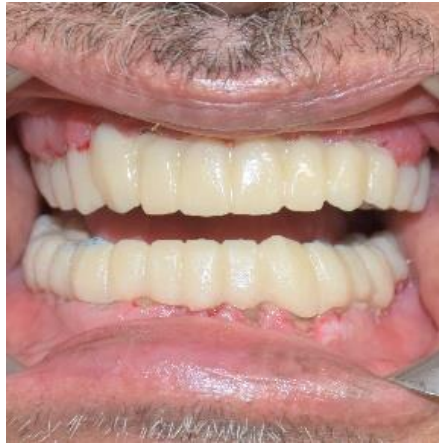

Figure 13: Case 3 Post-operative.

- **Functional outcome:** Restoration of anterior guidance and posterior support, with patient reporting improved chewing efficiency.
- **Biological outcome:** Radiographic follow-up at 1 year showed stable periapical status and bone levels; no post debonding or root fracture detected as shown in Figure 14.

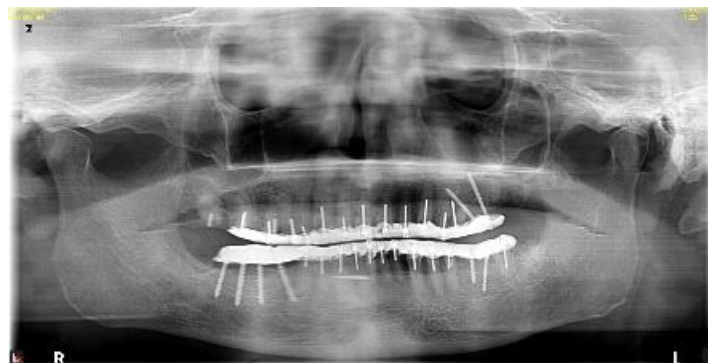


Figure 14: Case 3 Post-operative OPG.

DISCUSSION

This case series highlights how carefully selected teeth with severely compromised coronal structure can be predictably restored when biological principles and contemporary materials are respected. Rather than assuming extraction and implant placement as the default solution, the present cases reinforce the philosophy of retaining natural roots whenever biomechanically feasible.

Preservation of natural roots whenever feasible

A recurring theme in restorative literature is that the prognosis of endodontically treated teeth (ETT) depends largely on remaining dentin and the presence of a ferrule, rather than the mere presence or absence of a post. [3–5,13,18]

Citation: Chirag Chamria (2025) Saving Natural Root Pieces with Post-and-Core and Polymer Reinforced Crowns: A Clinical Case Series. On J Clin & Med Case Rep 2(1): 1-13.

Systematic reviews comparing restored ETT versus implants have shown similar long-term survival outcomes when the restorative protocol for ETT is properly executed. [1–6] Additionally, the biologic advantage of retaining roots extends beyond mastication—root-submergence and decoronation protocols have demonstrated preservation of the alveolar ridge and peri-implant soft-tissue form even when coronal tooth structure is absent. [7–10] Thus, when roots are periodontally sound and restorable, evidence supports retaining them before considering extraction and implant placement.

Post-and-core build-up with ferrule and cuspal coverage

The biomechanical success of the restored teeth across the three presented cases is attributed to adherence to a structured protocol: respecting the apical seal during post-space preparation to avoid microleakage; using adhesive or mechanically retentive metal posts where indicated; achieving a circumferential ferrule of 1.5–2.0 mm with core build-up; and providing full-coverage indirect restorations to ensure uniform stress distribution. Large cohort studies and meta-analyses consistently report survival rates of 83–95% over 5–10 years for ETT restored with ferrule and cuspal coverage [1–4,6,11,12,17,18]. Failure in such teeth is most commonly associated with insufficient ferrule height and parafunctional loading rather than the post material itself. [3–5]

Advanced polymer-reinforced crowns in full-arch rehabilitations

Polymer-reinforced high-performance PMMA formulations—such as graphene-enhanced G-CAM—are gaining acceptance as definitive restorative materials, especially for full-arch frameworks. Manufacturer data and early independent studies indicate better flexural strength, wear resistance, and colour stability compared with conventional PMMA. [11,14–16] Importantly, their slight flexural resilience and shock-absorption properties may help reduce the risk of catastrophic root fractures—one of the most severe complications in post-and-core high-load situations. While long-term, independent clinical data are still emerging, initial clinical experience and laboratory investigations support their use in carefully selected definitive cases.

Overall clinical implications

The present case series underscores that “good roots with bad crowns” do not automatically require extraction. When periodontal stability, restorative ferrule, and occlusal protection can be achieved, post-and-core rehabilitation with modern polymer CAD-CAM prostheses provides a biologically conservative, cost-efficient, and durable alternative to implant-based full-arch solutions. At a broader clinical level, dentists must balance biologic cost, functional longevity, and patient-specific needs rather than relying on implant-first treatment planning. Continued follow-up of such rehabilitations, combined with emerging material-science evidence, will further refine selection criteria for long-term success.

CONCLUSION

1. Endodontically treated teeth with minimal coronal structure can still be salvaged when the roots are structurally and periodontally sound and a ferrule-oriented post-and-core is feasible.

Citation: Chirag Chamria (2025) Saving Natural Root Pieces with Post-and-Core and Polymer Reinforced Crowns: A Clinical Case Series. On J Clin & Med Case Rep 2(1): 1-13.

2. Modern metal posts, adhesive cores and PMMA reinforced CAD-CAM crowns support a conservative, biomechanically favourable approach to such cases.
3. Full-mouth rehabilitation over preserved roots is a clinically realistic alternative to extensive extraction-and-implant schemes, particularly where patients prefer to retain their natural dentition, avoid extensive surgery, or optimize cost.

LIMITATIONS

The follow-up periods for the presented cases are relatively short and vary among patients. While early outcomes are favourable, long-term clinical data on polymer-reinforced definitive prostheses are still emerging. Larger controlled studies with standardized follow-up intervals are needed to validate long-term performance trends.

CLINICAL SIGNIFICANCE

This case series supports a “root-first” treatment philosophy: before planning extraction and implants in apparently hopeless teeth, clinicians should systematically evaluate root quality, ferrule potential and the possibility of post-and-core reconstruction using contemporary materials such as posts and graphene-reinforced crowns.

ETHICAL CONSIDERATIONS

Written informed consent was obtained from all patients for treatment and publication of anonymized clinical data and photographs. This study did not require institutional ethical board approval as it is a retrospective clinical case series with no experimental intervention.

REFERENCES

1. Bhuva B, Giovarruscio M, Rahim N, Bitter K, F Mannocci (2021) The restoration of root filled teeth: a review of the clinical literature. *Int Endod J* 54(4): 509-535.
2. Tsintsadze N, Juloski J, Mariam Margvelashvili-Malament, Zuhair S Natto, Marco Ferrari (2024) Comparing survival rates of endodontically treated teeth restored either with glass-fiber-reinforced or metal posts: a systematic review and meta-analyses. *J Prosthet Dent* 131(4): 567-578.
3. Ayu Trisna Hayati, Diani Prisinda, Alodia Luna Latifa Nugroho (2025) Survival and success rate of restoration post-endodontic treatment: a systematic review. *Clin Cosmet Investig Dent* 17: 525-537.
4. Saja K Al-Meshal, Aqeel M AlismaiI, Tamim A Alfalah, Abdulaziz S AlRashidi, Hadeel J Al-Mubarak, et al. (2025) Remaining tooth structure and prognosis of restored endodontically treated teeth: a systematic review. *Cureus* 17(10): e94406.
5. Juloski J, Radovic I, Goracci C, Vulicevic ZR, Ferrari M (2012) Ferrule effect: a literature review. *J Prosthet Dent* 107(6): 369-374.
6. Ali A Alenezi, Sreen O Alyahya, Noura S Aldakhail, Hanin A Alsalhi (2024) Clinical behavior and survival of endodontically treated teeth restored with posts and cores. *J Oral Sci* 66(4): 207-214.

7. Sunyoung Choi, In-Sung Yeo, Sung-Hun Kim, Jai-Bong Lee, Chan Wook Cheong, et al. (2015) A root submergence technique for pontic site development in fixed dental prostheses in the maxillary anterior aesthetic zone. *J Periodontal Implant Sci* 45(4): 152-156.
8. Jonathan Du Toit, Maurice Salama, Howard Gluckman, Katalin Nagy (2023) Root submergence technique as a partial extraction therapy in restorative and implant dentistry. *J Prosthet Dent* 130(2): 187-201.
9. Malmgren B (2013) Ridge preservation/decoronation. *J Endod* 39(3 Suppl): S67-S72.
10. Jaikaria A, Seema T (2019) Alveolar ridge preservation in a growing patient with decoronation of ankylosed tooth. *J Clin Pediatr Dent* 37(2): 214-217.
11. Graphenano Dental (2023) G-CAM Graphene-reinforced biopolymer disc for CAD/CAM milling – Product catalogue Volume 4.
12. Graphenano Dental. Graphenano Dental – Graphene in definitive dental prostheses.
13. Pinto ABA, Guilherme Schmitt de Andrade, Amjad Abu Hasna, Joyce Rodrigues de Souza, João Paulo Mendes Tribst, et al. (2024) Can the remaining coronal tooth structure influence the mechanical behavior of full crowns on endodontically treated teeth? *J Prosthodont Res* 18(2): 652-664.
14. Helena Salgado, Patrícia Fonseca, Mário Vaz, Maria Helena Figueiral, Pedro Mesquita (2022) The use of graphene for dental polymethylmethacrylate: a systematic review. *Rev Port Estomatol Med Dent Cir Maxilofac* 63(4):179-188.
15. Beleidy M, et al. (2025) Wear resistance and surface roughness of graphene-reinforced PMMA after artificial aging.
16. Banode V, et al. (2024) Effect of graphene reinforcement on the color stability of provisional fixed dental prostheses. *J Int Clin Dent*.
17. Hatice Harorlı, Simay Koç, Yunus Emre Çakmak, Damla Erkal, Kürşat Er (2025) Survival of root canal-treated teeth with fiber-reinforced post restorations: a retrospective study. *Turkiye Endod J* 10(1): 17-22.
18. Meghana Aditya Vartak, Vibha Rahul Hegdeorcid, Sanitra Rahul Hegdeorcid, Ushaina Fanibunda (2025) Fracture strength of Ribbond and other post systems: a systematic review and meta-analysis of in vitro studies. *Restor Dent Endod* 50(1): e5.